

# Genitalia Examination

---

## Evidence Collection/Injury Documentation

- **External Genitalia**
  - Initial Inspection
  - Collection of Evidence
  - Detailed Inspection
  - Injury Identification/Photography
  - TB Dye/Photography/Advanced Skills
  - Documentation

## Evidence Collection/Injury Documentation

During ano-genitalia examination initial direct visualization should be done first to identify any traumatic injuries that may need ***priority medical intervention***

## Evidence Collection/Injury Documentation

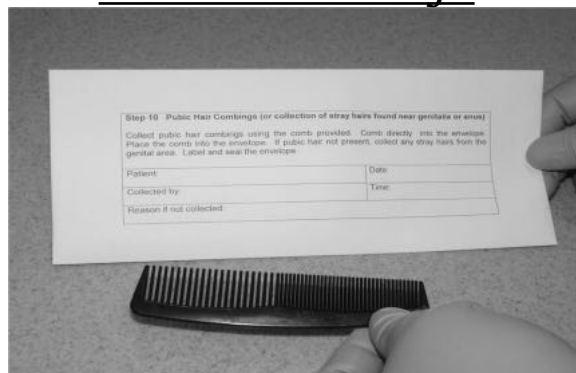
Steps:

- Pubic Hair combing***
- Anal assessment***
- External vaginal assessment***
- Internal vaginal assessment***

# Evidence Collection

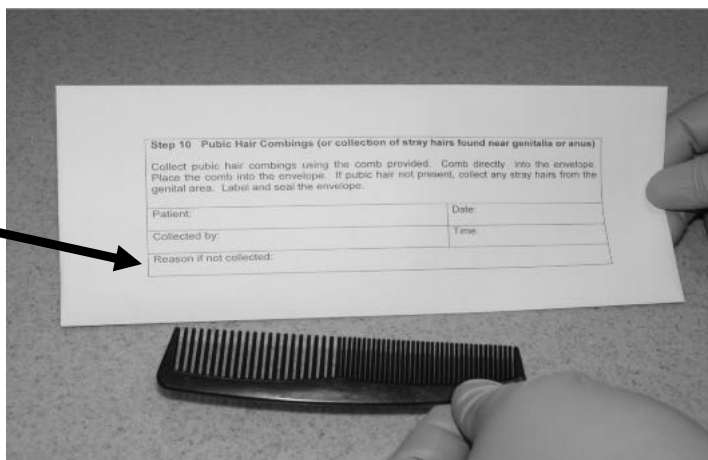
## Collection of Evidence

### -Pubic Hair Combings-



# Evidence Collection

## Collection of Evidence



## Evidence Collection

### -Pubic Hair Combing-

- Explain procedure to patient
- Ensure dignity, draping, people in room
- Use supplies provided in kit
- Technique (comb into provided envelope)
- Matted hair or clumps (consider sterile scissors to remove instead of combing to avoid pain)

## Evidence Collection

### -Pubic Hair Combing-

- Should be performed REGARDLESS of shaved mons pubis
- Rationale: any debris/FB in area may be identified at the crime lab
- Notation should be made that the patient shaves mons pubis but step still performed

## Evidence Collection

### -Pubic Hair Combing-

- Place envelope in between legs of patient and comb towards the envelope opening
- Place comb inside the envelope
- Close envelop and label
- CHANGE GLOVES > proceed to next step

## Anal Examination

# Evidence Collection

## Collection of Evidence

### -External Anal Samples -



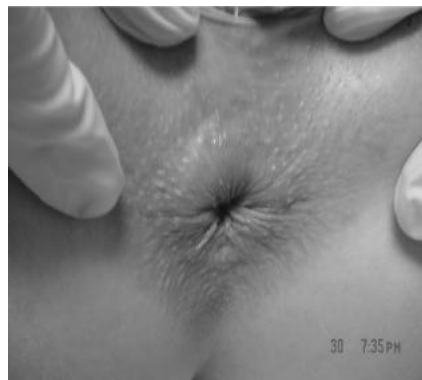# Evidence Collection

## Collection of Evidence

### -External Anal Samples -

**NEVER** collect internal anal samples

**ONLY** external samples



# Evidence Collection

## Collection of Evidence

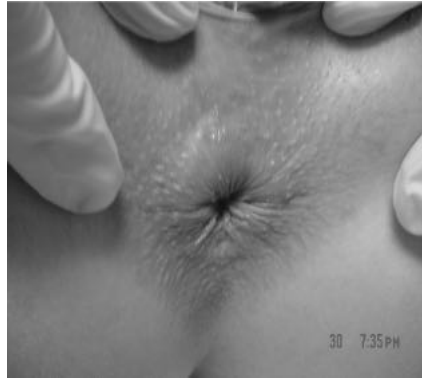### -External Anal Samples -

#### 1. INSPECTION

Stretch anus opening to allow folds to be viewed to assess for any injury

(helpful to use additional lighting)

**\*\*MUST use lighted magnifier**



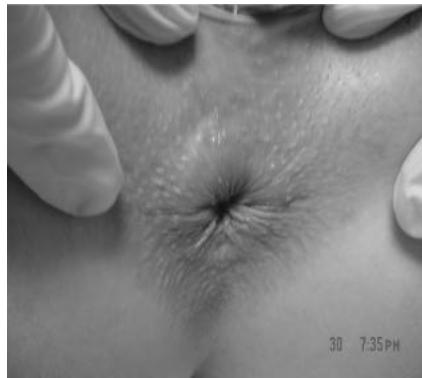# Evidence Collection

## Collection of Evidence

### -External Anal Samples -

**Photograph ANY findings prior to proceeding to DNA collection**

***Rationale: defense attorney may claim YOU caused the injuries by swabbing or collection specimens***



# Evidence Collection

## Collection of Evidence

### -External Anal Samples -

**DNA collection**

**Total of 4 swabs**

**DRY STAINS (dry area of the body) so must use sterile water to moisten swabs.**

**X3 rule (3 drops, 3 rolls along skin)**



# Evidence Collection

## Collection of Evidence

### -External Anal Samples -

**Create slide smear mount for crime lab processing**

**Place swabs inside box and label accordingly**

**Place all items inside envelope and label envelope**

**Change gloves and proceed to next step**



## External Vaginal Assessment

## Evidence Collection

### Collection of Evidence

#### -External Anal Samples -

Assess entire external vulvar region PRIOR to specimen collection

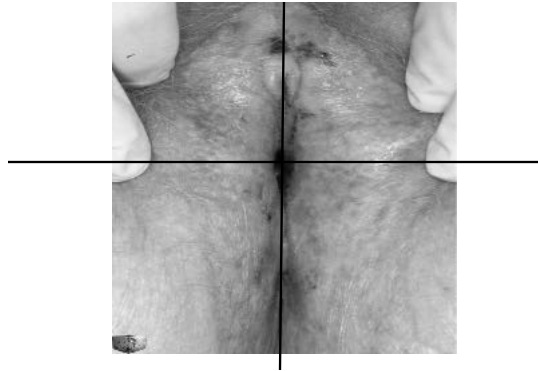
\*same rationale as before – never place yourself in a situation that a defense attorney could speculate that YOU caused the injuries. It is common to cause micro injuries with specimen collection or speculum examination

\*\*Must use additional lighting AND magnification

## Injury Identification and Documentation

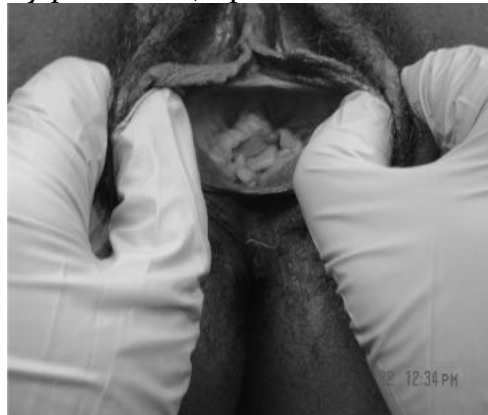### Initial Inspection

*\*Initial visual inspection should be completed in quadrants or sections to assure no areas are overlooked to assess if injuries need immediate attention.*



## Identification and Documentation

*\*After specimen/swab collection and initial visual inspection begin to maneuver genital folds/skin to reveal injury presence (separation and traction)*

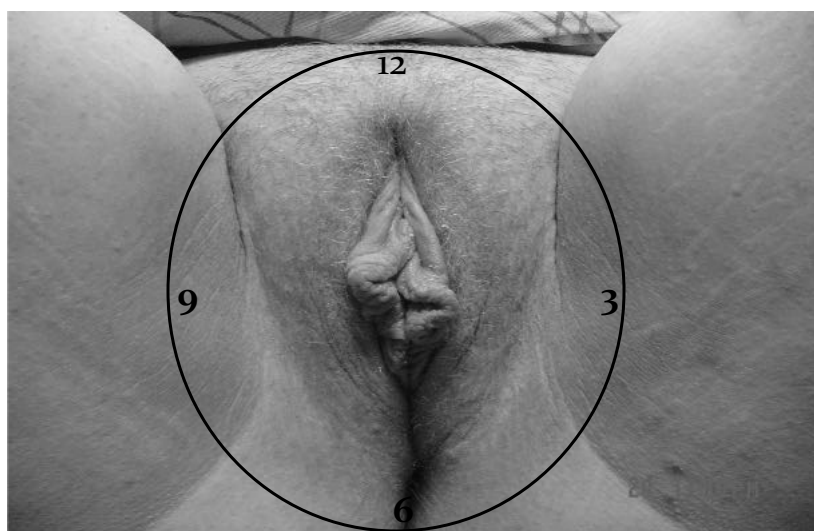


## Identification and Documentation

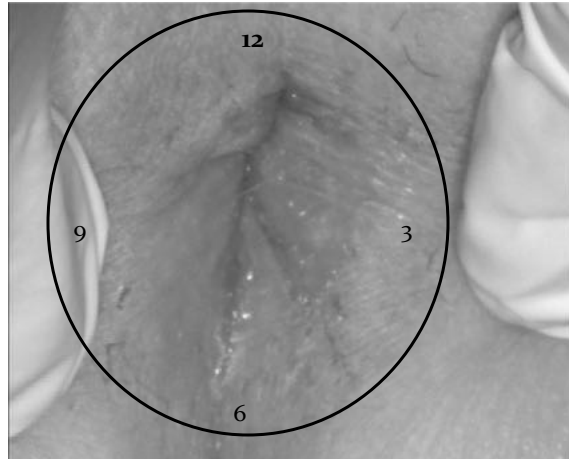
*\*Documentation and identification of all injuries should be charted using the o'clock method for location of the injury*



## Identification and Documentation



## Identification and Documentation



Laceration to anus at 12, 4 and 6 o'clock

## Identification and Documentation

Additional information to chart:

- \*Pain reported by patient
- \*Tolerance of pelvic examination
- \*Anatomical variations found
- \*Fluid/Bleeding (and source if known or able to locate)
- \*ANY findings
- \*Debris or Foreign Bodies

## Identification and Documentation


AVOID using language such as:

\*Drainage (example – fluid found in vaginal vault if drainage is used it may imply that source is patient and it may be from the perpetrator) ***alternate word is “fluid”***

## Identification and Documentation

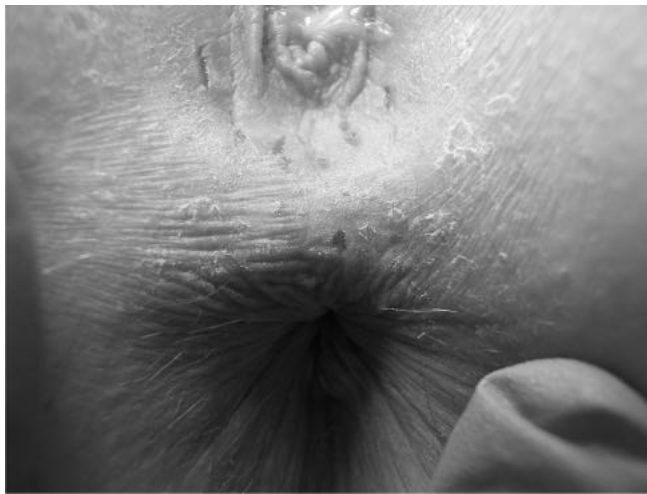***Injury Identification and Documentation***

## Identification and Documentation



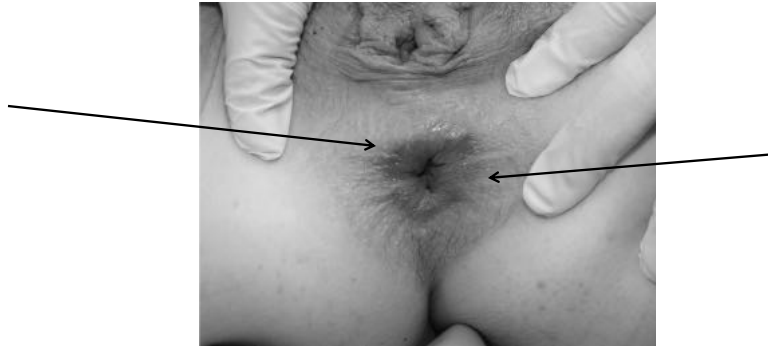
Tear to anus at 6'oclock, redness to anus from 5'oclock to 7'oclock

## Identification and Documentation



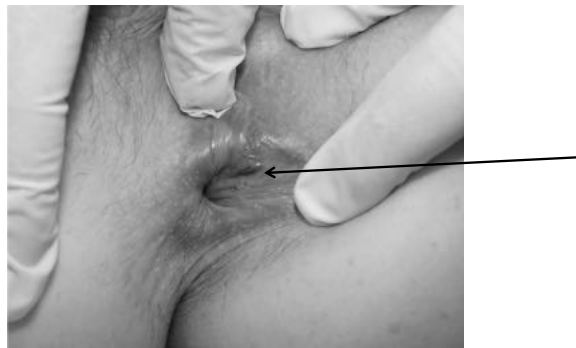
Multiple tears to fossa navicularis at 4, 5, 6, 7 and 8 o'clock and perineum at 12 o'clock (measure each & describe)

## Identification and Documentation



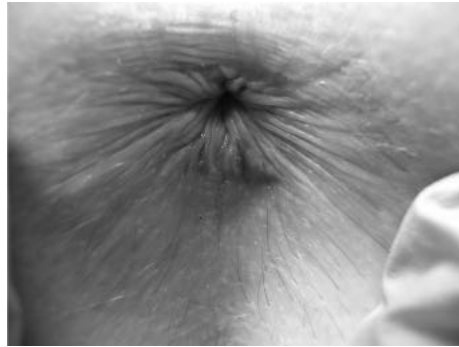circumferential ecchymosis to anus  
Swelling noted to anus from 11 o'clock to 2 o'clock

## Identification and Documentation



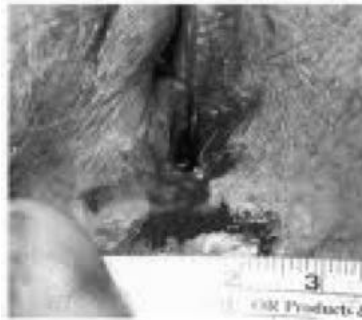Tear to anus at 2 o'clock  
(Sterile water has been used to clear acute bleeding)

## Identification and Documentation



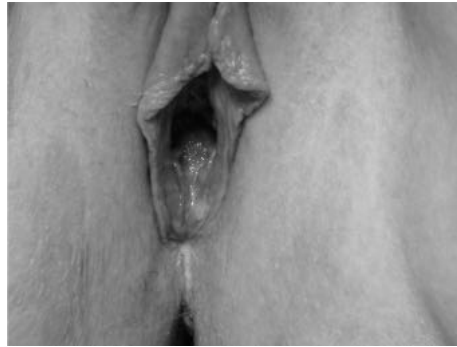X3 tears noted to anus at 5:30, 6 o'clock and 6:30

## Identification and Documentation



Acute bleeding from vaginal vault

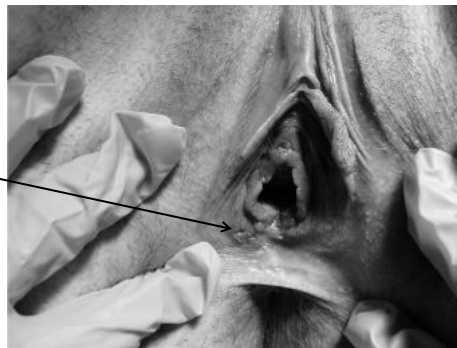## Identification and Documentation



White/purulent colored fluid draining from vaginal vault

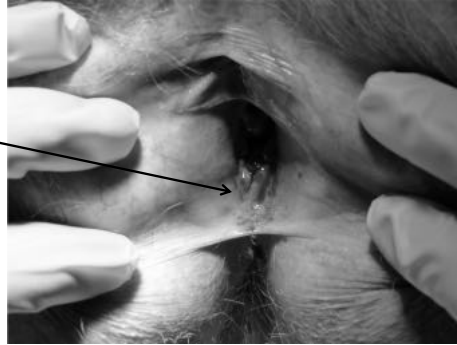## Identification and Documentation

Saline has been used  
To displace acute bleeding  
from injury



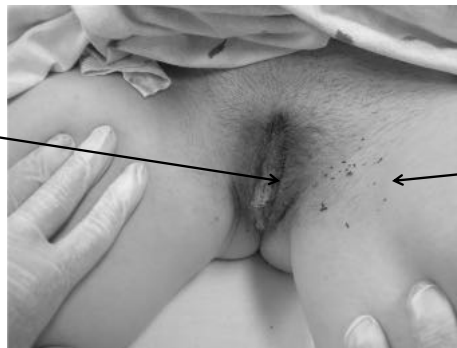Tear to medial Labia Minora fold at 7 o'clock

## Identification and Documentation



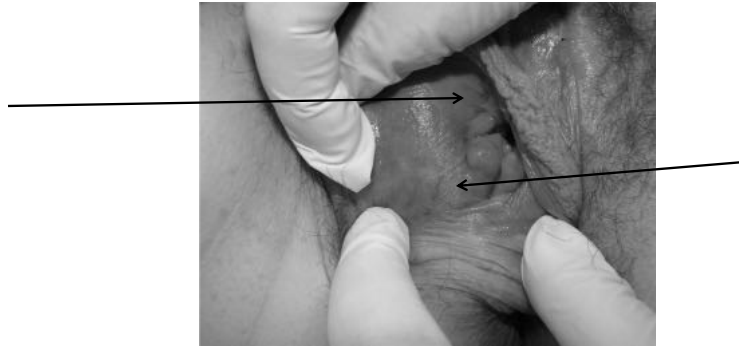
Tear to hymen at 7 o'clock – acute bleeding from vaginal vault

## Identification and Documentation



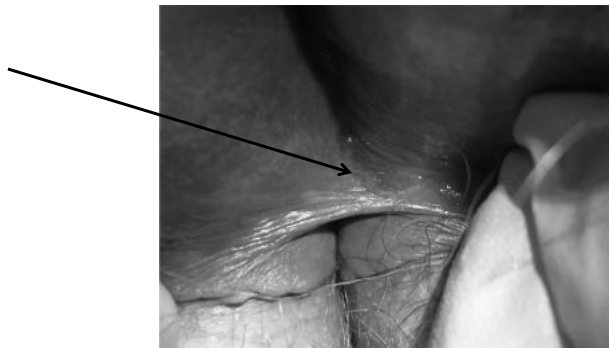
Debris noted to labia Majora at 3 o'clock  
Debris noted to Inguinal folds from 2 o'clock to 5 o'clock  
Photograph + collect debris sample + document in detail

## Identification and Documentation



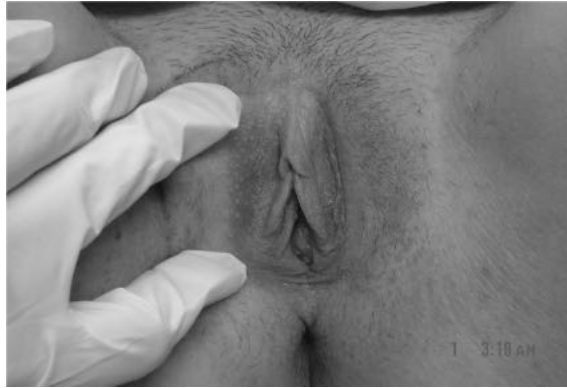Redness noted to labia minora at 8 o'clock  
Ecchymosis noted to hymen from 9 o'clock to 11 o'clock

## Identification and Documentation



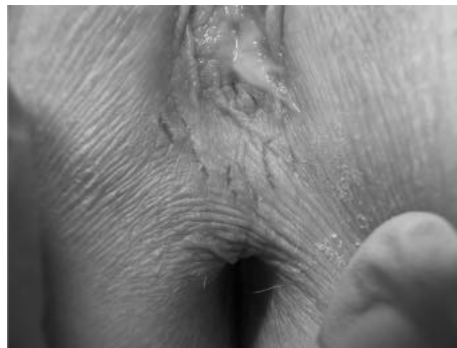Redness to Fossa Navicularis at 6 o'clock

## Identification and Documentation



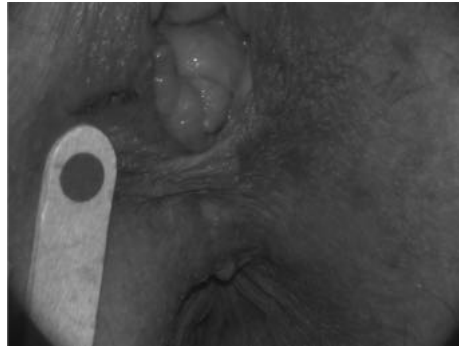Redness to Right labia minora from 7 o'clock to 11 o'clock

## Identification and Documentation



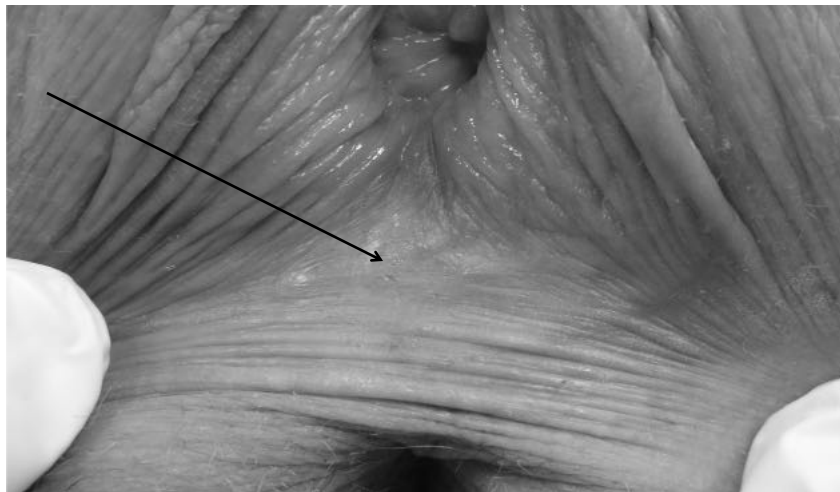
Yellow fluid from vaginal vault, x5 tears to perineum from 5 o'clock to 7 o'clock

## Identification and Documentation



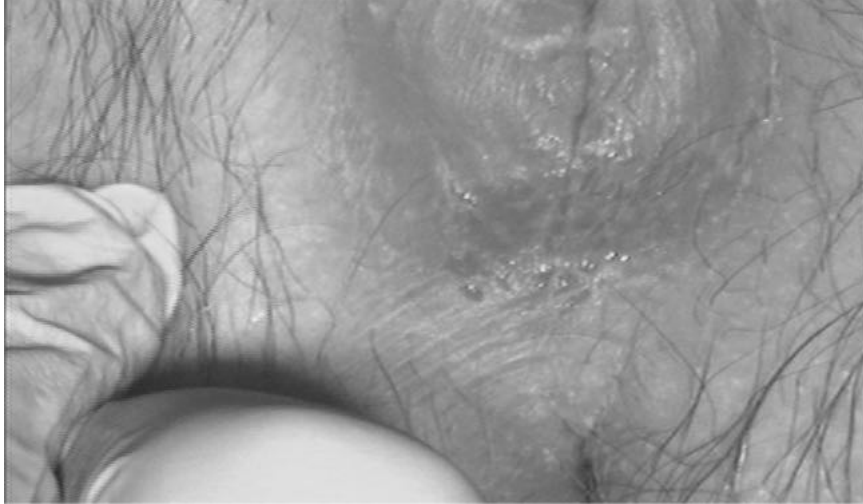
Tear noted to Labia minora at 9 o'clock

## Identification and Documentation



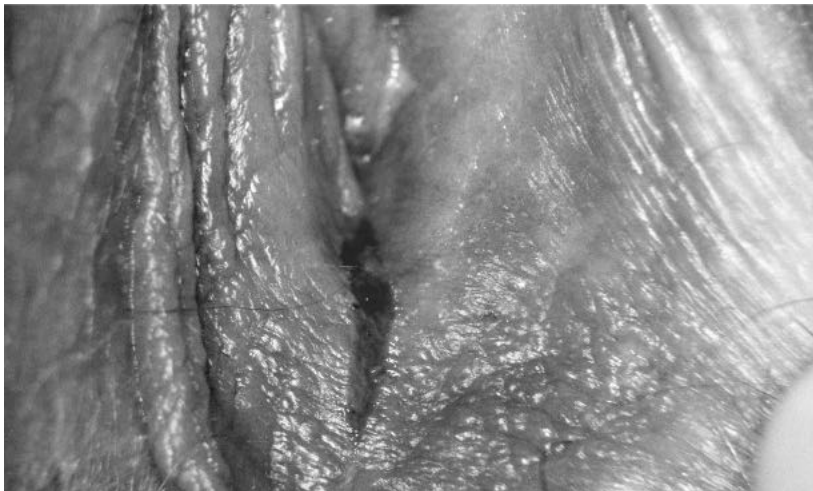
Tear to posterior fourchette at 6 'clock

## Identification and Documentation



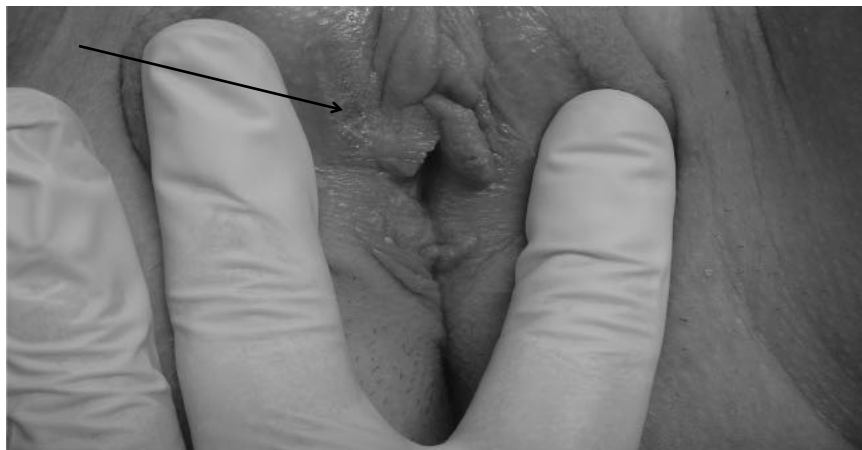
Multiple tears to posterior fourchette and fossa navicularis from 5'oclock to 7'oclock

## Identification and Documentation



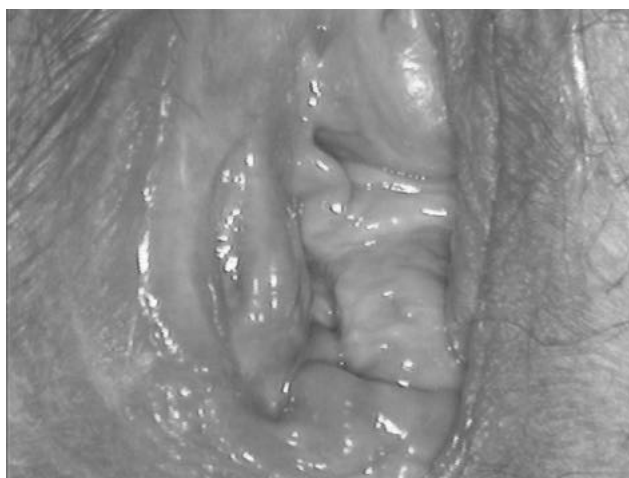Linear Tear to posterior fourchette and fossa navicularis at 6 'clock

## Identification and Documentation



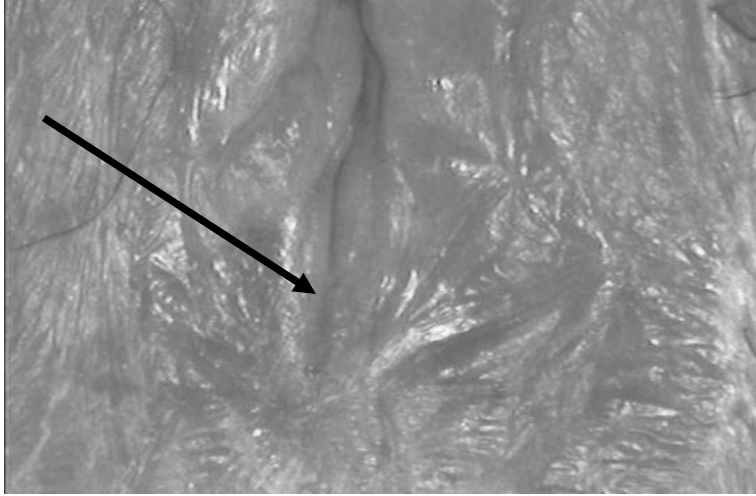
Abrasion and redness to labia minora at 9 o'clock

## Identification and Documentation



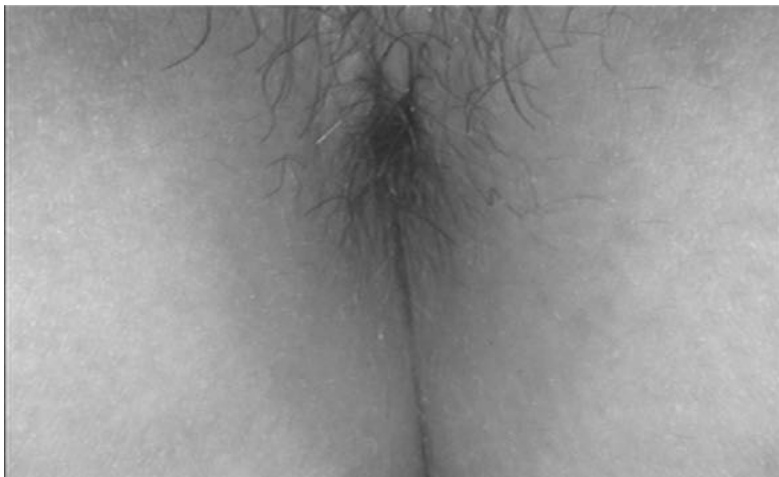Swelling and redness to hymen from 6 o'clock to 12 o'clock

## Identification and Documentation



Tear to fossa navicularis at 6 'clock

## Identification and Documentation



Patterned annular redness to perineum from 3:00 to 9:00

## Advanced Skills / Procedures

### Specialized Procedures

#### Foley Catheter Technique - What is it?

- **Foley catheters are a great tool to aid in visualization of hymenal injuries**
- **Insertion of a foley catheter into the vaginal vault to assist in visualization of injuries specifically to the hymen**

## Specialized Procedures

### Foley Catheter Technique - How to perform

- **Insert a de-inflated foley catheter tip slightly into the vaginal vault.**
- **Inflate the balloon of the foley catheter with 10-12 cc of sterile water while the tip remains in the vaginal vault passed the hymen**
- **Slowly begin to withdraw the inflated foley catheter from the vaginal vault until the balloon is on the immediate posterior side of the hymen**

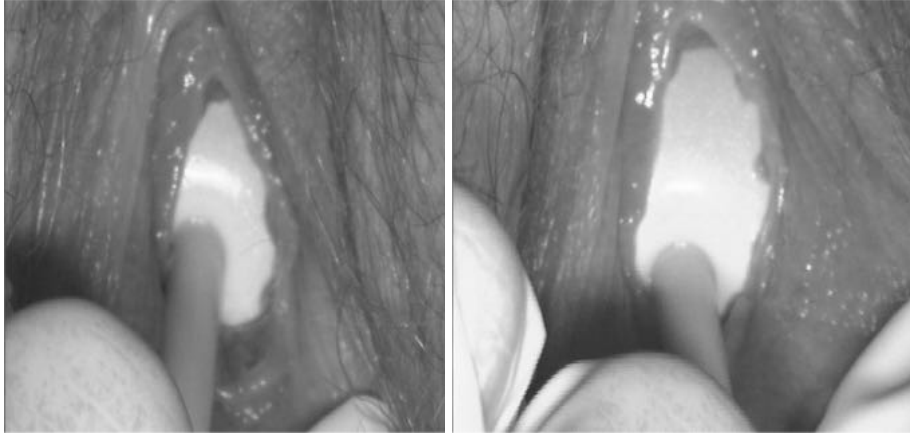
## Specialized Procedures

### Foley Catheter Technique - How to perform

- **Once the balloon begins to expand the hymen observe for injuries and document if present.**
- **Extremely effective for photographs of injuries specifically to estrogenized hymens.**

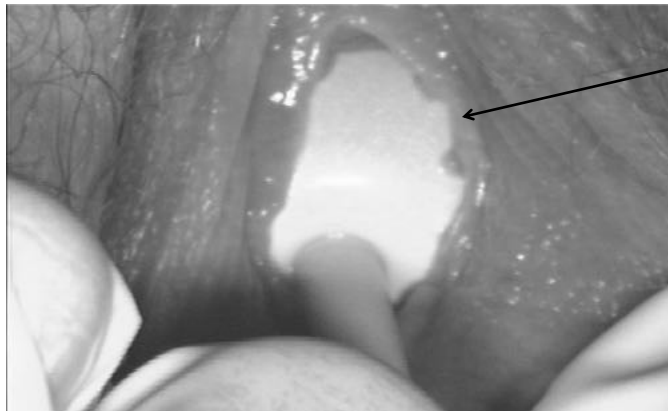
## Specialized Procedures

### Foley Catheter Technique



## Specialized Procedures

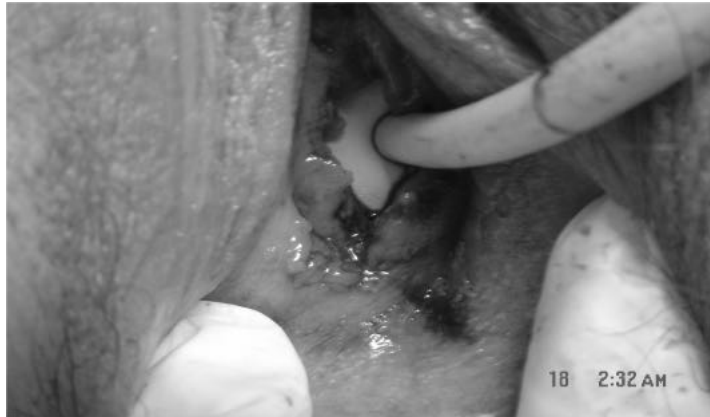### Foley Catheter Technique



Tear to hymen at 2'oclock

## Specialized Procedures

### Foley Catheter Technique



Tear to hymen at 7'oclock

## Specialized Procedures

### Foley Catheter Technique

- Once injuries are photographed (before FC technique and after) remove sterile water from balloon and remove from vaginal vault

**Use sterile scissors to cut tip of foley and place in kit for processing at crime lab**

# Evidence Collection

## Collection of Evidence


### -External Vaginal Samples -

#### DNA collection

**Total of 4 swabs (2 for internal and 2 for external)**

**DRY STAINS (dry area of the body) so must use sterile water to moisten swabs.**

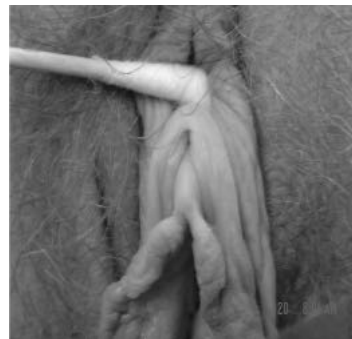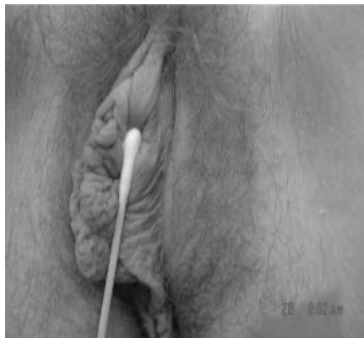**X3 rule (3 drops, 3 rolls along skin)**



# Evidence Collection

## Collection of Evidence

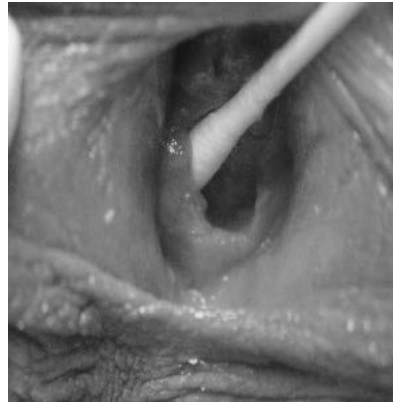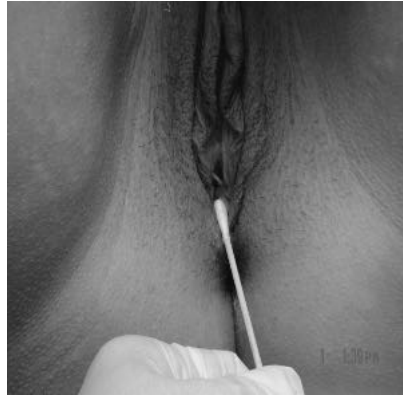### -External Vaginal Samples -



## Evidence Collection

### Collection of Evidence

#### -External Vaginal Samples -



## Declines Speculum Exam

\*If your patient declines the speculum exam you should STILL collect external vaginal swabs, CLEARLY explain request to patient and proceed with external collection (should document WELL what patient choices have been made)

Document on diagrams AND on nursing note that the patient declined speculum exam

Encourage patient to proceed due to possibility of FB, injury, DNA collection that may go unassessed if they decline

## Evidence Collection

Collection of Evidence

-External Vaginal Samples -



## Evidence Collection/Injury Identification and Documentation

**Internal Vaginal Examination-Evidence Collection  
on additional video**

**\*\*Pearl: wear two sets of gloves so you can easily  
remove one set of gloves in between the anal  
assessment and the speculum exam**

# Genitalia Assessment

Questions?