

## SPECULUM EXAMINATIONS

## SPECULUM EXAMINATIONS

Types of speculums:

- Pederson
- Graves
- Pediatric

## SPECULUM TYPES

- Pederson – closed sides, regular and long length
- Graves – open sides, wider (duckbill), regular and long length
- Pediatric – pediatric or geriatric patients, vaginal stenosis

\*\*Pederson is usually the specula of choice for most examiners

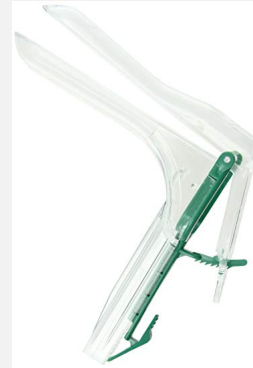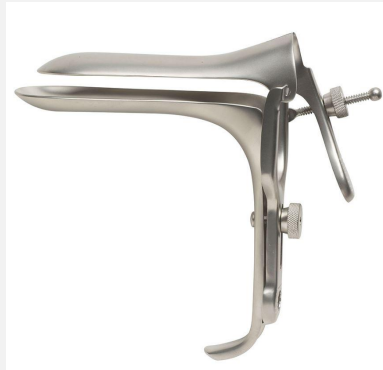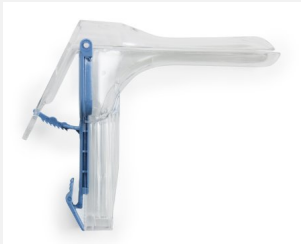## PEDERSON SPECULUM

- Pederson – closed sides, regular and long length




## GRAVES SPECULUM

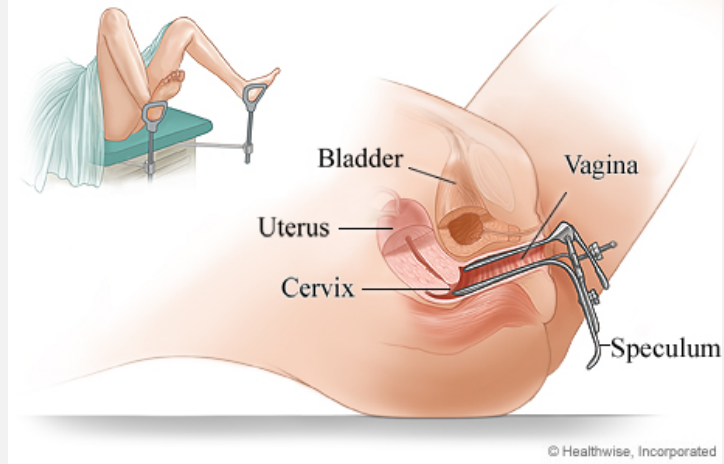
- Graves, – open sides, (duckbill) – regular and long



## COMPARISON

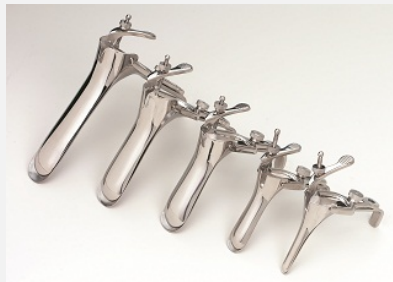

## SPECULUM INSERTION



## PEDIATRIC SPECULUM

Pediatric Speculum – peds or geriatric patients, vaginal stenosis



## HISTORY

- Always confirm patient's OB-GYN history
- GTPAL = should be obtained prior to speculum
- Gravida – # of pregnancies in lifetime
- Para – subset of TPAL
- T - # of term pregnancies
- P - # of preterm pregnancies (<37 weeks)
- A - # of abortions
- L - # of living children
- Can report as G:P = example G3:P3 or written out in full GTPAL

## GTPAL

- GTPAL should also be included in report to the physician
- Example G2:P0
- Forensic considerations for GTPAL is findings/conditions of cervix
- Findings on cervix may be related to normal anatomical findings related to GP hx

## ADDITIONAL HISTORY

- Salpingo – oophorectomy
- Hysterectomy (complete or partial)
- STDs (recent or current)
- Trauma
- Cancer
- Cystocele
- Prolapsed uterus
- Polyps
- Any other medical history related to the vaginal vault

## CONCERN FOR PATIENT SAFETY

- Any time the patient has a condition that has protrusions or bulging area from the vaginal vault, the physician should perform the speculum examination with your assistance for collection of swabs and photography of findings

## SPECULUM EXAM

- After obtaining full OBGYN hx, patient has no protrusions, bulging, areas of concern from the vaginal vault > proceed with the speculum examination
- Fully explain the procedure to the patient step by step
- Important to assess if the patient has had a speculum exam prior and assess previous comfort level of speculum exams
- HAVE THE CALL LIGHT WITHIN REACH of yourself or the patient
  - \*if there are emergency findings during the speculum exam you will be able to contact the staff and request the physician promptly to the room

## SPECULUM EXAM

- The patient should be made aware that any portion of the exam may be declined or omitted
- Allow the patient to make full decisions on progressing
- Exam can be stopped at any time

## SPECULUM EXAM

- If patient declines speculum exam, make sure the patient is aware that it is critical to assess for injury, FB, findings AND possible DNA sources
- Ultimately, it is still the patient's decision on how to proceed

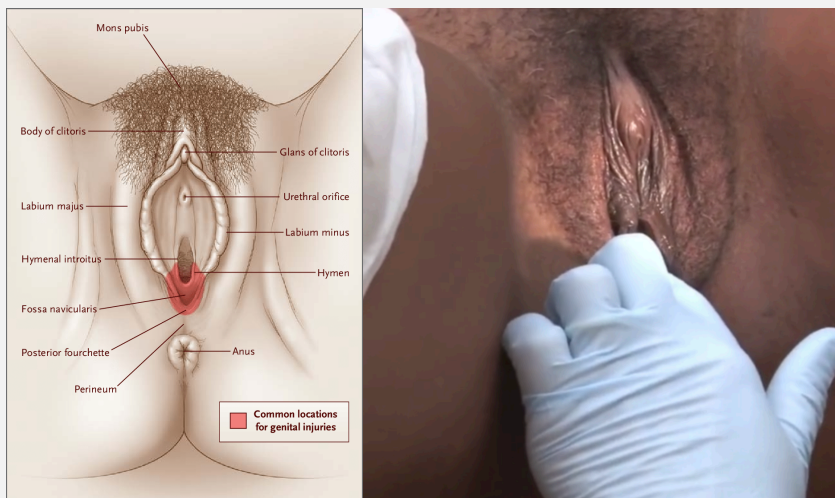
## SCOPE OF PRACTICE

- Speculum exams are within the scope of practice for Forensic Examiners/SANEs however the full pelvic examinations with palpation of internal orifices are NOT
- \*\*remember you are permitted to only perform the speculum examination. Internal palpation of the vaginal vault or insertion of any digits/fingers into the vaginal vault or anus is NOT within the scope of practice of a Forensic Examiner/SANE
- Responsible for identifying, photographing, collecting forensic samples from internal vaginal vault

## SPECULUM EXAM

- Request pelvic bed (at initial arrival to hospital)
- Prepare all necessary items PRIOR to beginning the speculum exam
- Have the patient buttocks near the end of the bed
- Place feet in stirrups (hospital staff may assist you in prepping bed if needed)
- Examine the external vulvar region closely (additional video for in depth review)
  - NOTE: extensive external examination, photography, specimen collection will occur PRIOR to the internal vaginal vault assessment (in separate video)

## SPECULUM EXAM



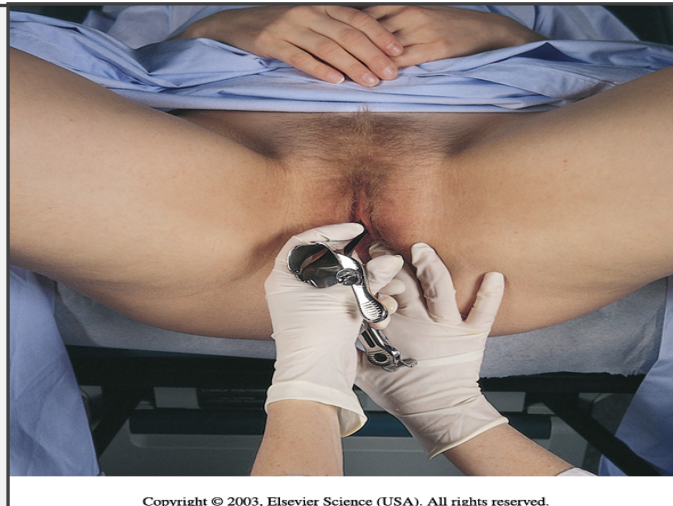- Advise the patient you will place your finger on the fossa navicularis region and show what muscles to request the patient to relax to allow easy insertion of the speculum into the vaginal vault

## SPECULUM EXAM



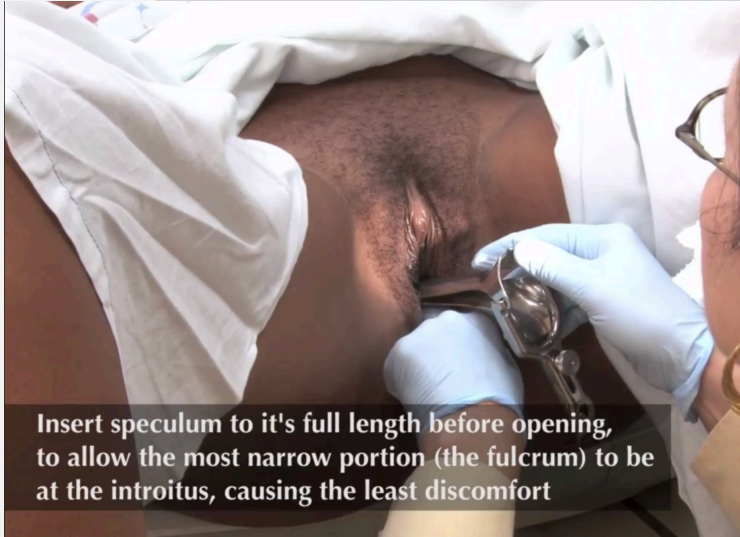- Place sterile lubricant jelly at end of speculum
- Insert the speculum **CLOSED** and turned to the side while advancing into the vaginal vault **and simultaneously turning to the upright position**
- Insert the speculum until slight resistance is felt and then **STOP** advancing

## SPECULUM EXAM



Copyright © 2003, Elsevier Science (USA). All rights reserved.

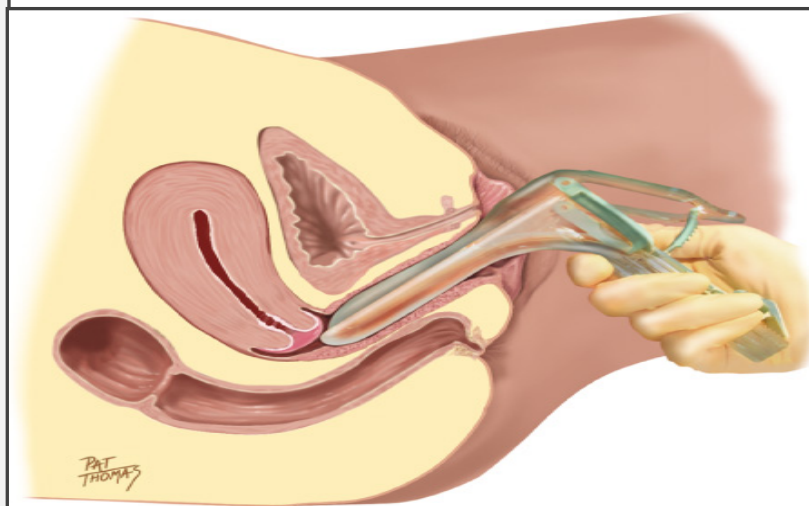
## SPECULUM EXAM



Insert speculum to it's full length before opening, to allow the most narrow portion (the fulcrum) to be at the introitus, causing the least discomfort

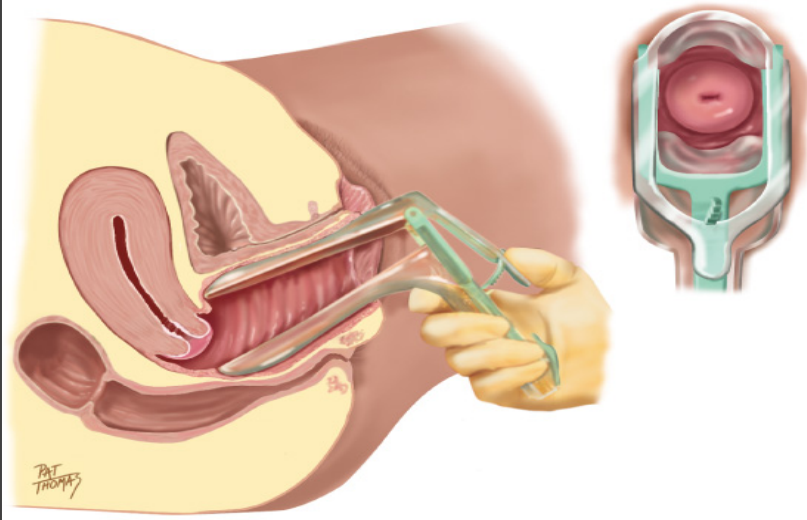
- Insert the speculum **CLOSED** and turned to the side while advancing into the vaginal vault and turning the speculum clockwise into the normal position
- Insert the speculum until slight resistance is felt and then **STOP** advancing

## SPECULUM EXAM



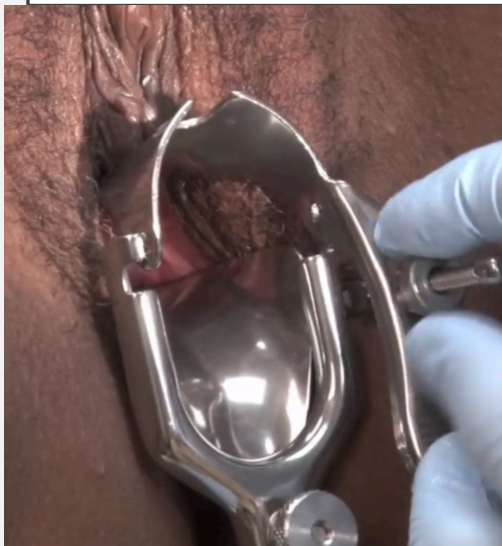Copyright © 2003, Elsevier Science (USA). All rights reserved.

## SPECULUM EXAM



Copyright © 2003, Elsevier Science (USA). All rights reserved.

## SPECULUM EXAM

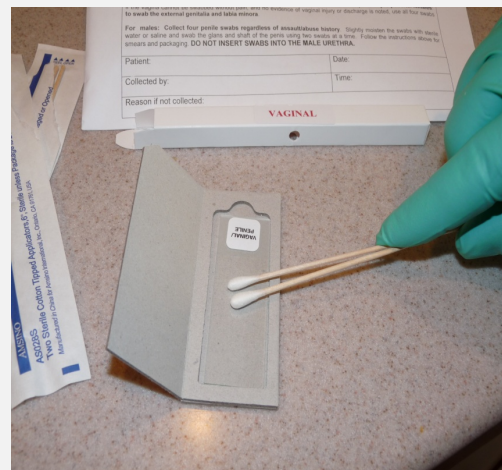
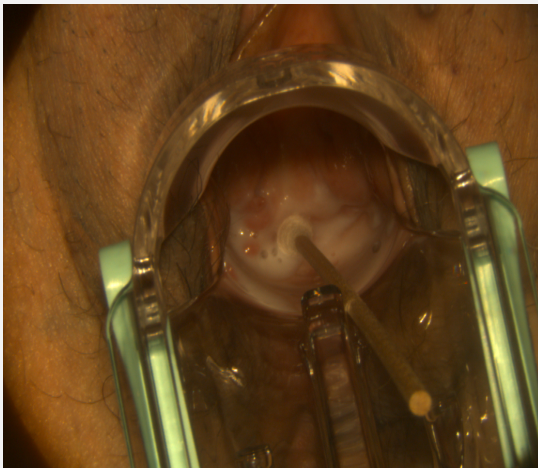


- Make sure the speculum is inserted completely **PRIOR** to opening
- When the speculum is fully inserted open the handle to allow viewing of the cervix
- **ONCE** the cervix is in sight lock the speculum open
- **ALWAYS** keep one hand on the speculum at all times

## SPECULUM EXAM

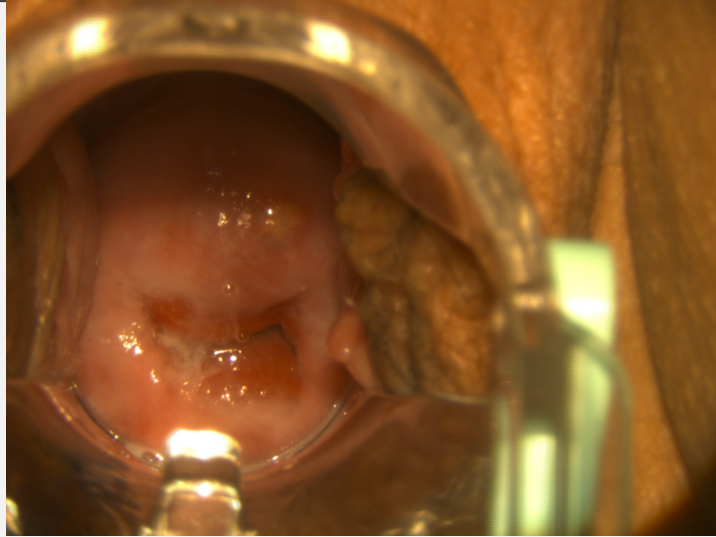
- Vaginal Vault Assessment:
- Foreign Body (if lodged through cervix do not remove)
- Cervical Os (IUD, open, closed, serous/sanguineous/purulent fluid, lesions, findings)
- Cervix (petechia, lesions, erythema, exudate, findings, etc)
- Vaginal walls (petechia, lesions, erythema, exudate, finding, etc)
- Pooled fluids
- PHOTOGRAPH **any findings** prior to specimen collection or FB removal
- Physician will review photos to determine further testing if warranted (STI)

## SPECULUM EXAM

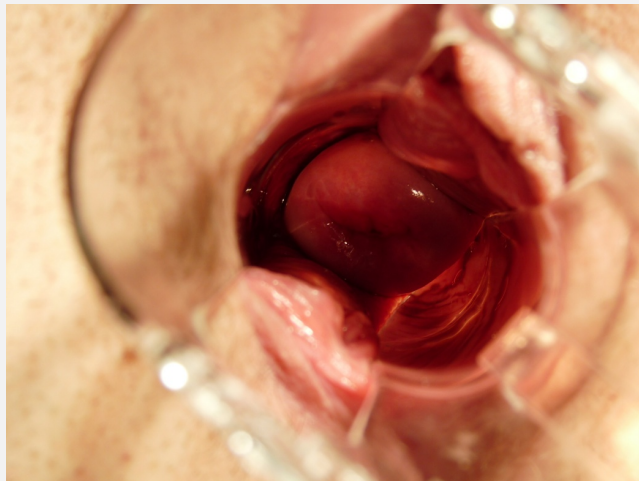

SPECULUM EXAM

Cervical ectropion –  
Non cancerous  
Endocervical cells observed at  
ectocervical location  
  
(cervical erosion)



SPECULUM EXAM



SPECULUM EXAM

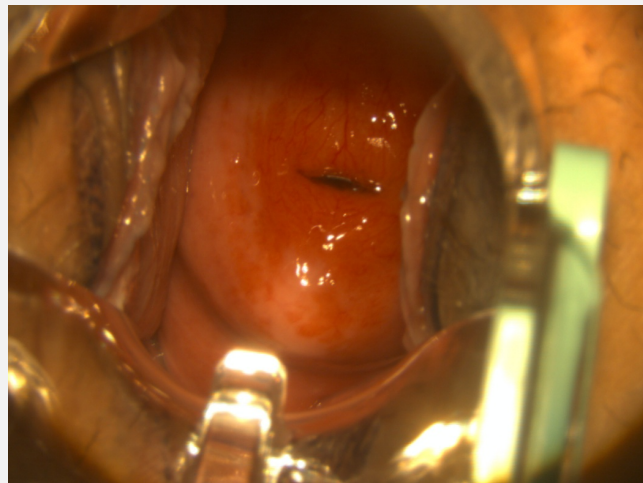


SPECULUM EXAM

Cervical OS open

Viscous clear fluid coating  
entire cervix

Circumferential redness/  
erythema noted to cervix



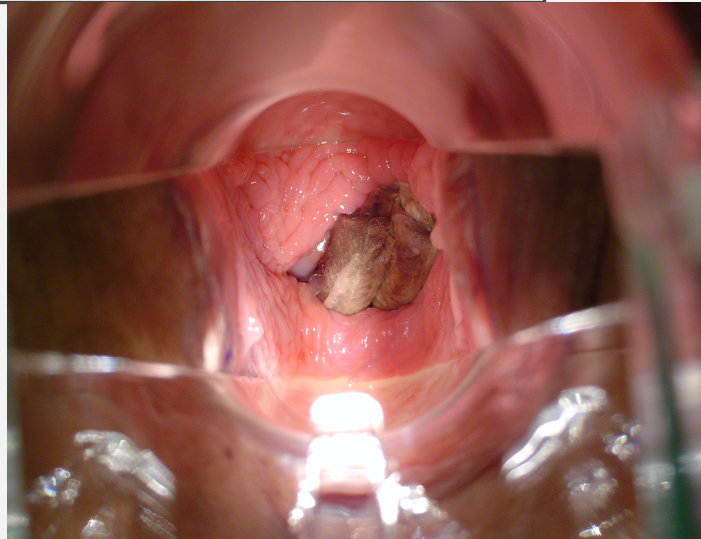
### SPECULUM EXAM

FB to vault

Photograph then remove FB

Place in sterile towels and  
place INSIDE kit to be  
processed at the crime lab

\*\*harbors tremendous amount  
of DNA

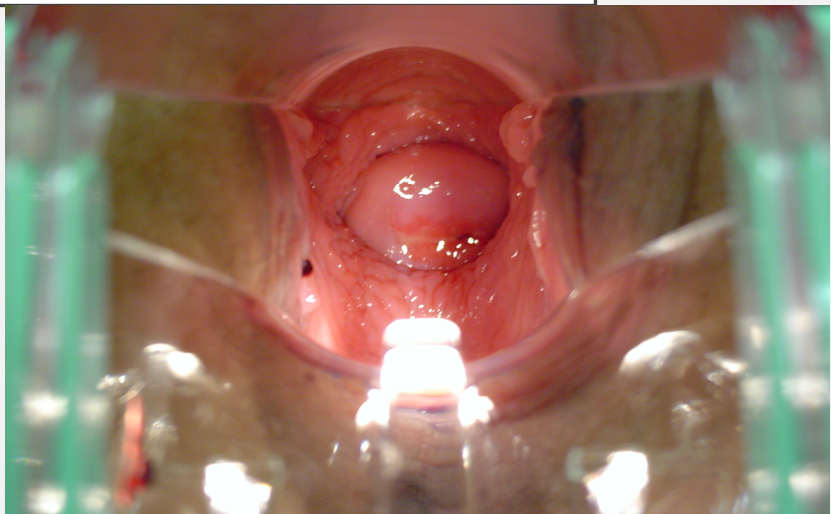


### SPECULUM EXAM

Posterior facing cervix

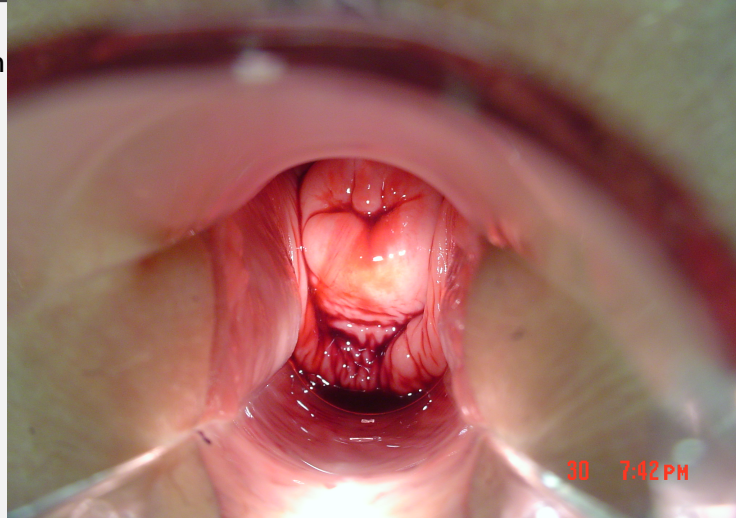
Redness from 9:00 to 1:00  
with irregular borders

Vaginal vault debris  
(photograph then remove  
To be sent in kit for  
processing)



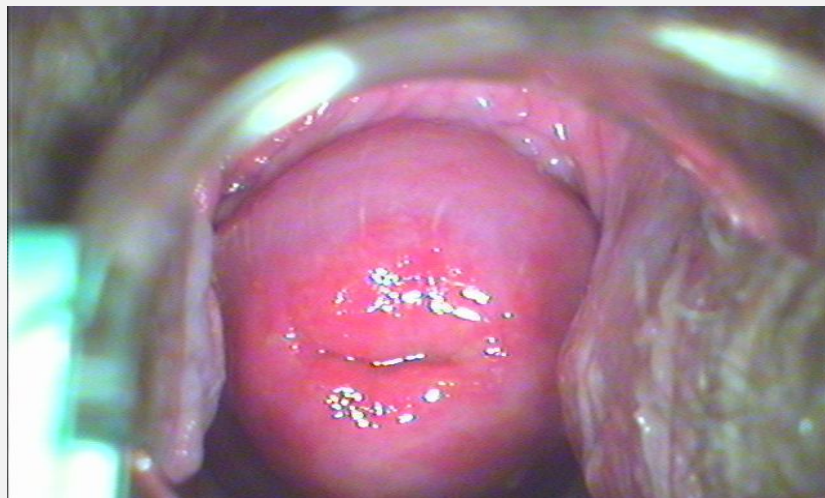SPECULUM EXAM

Sanguinous fluid from OS with pooling in posterior vaginal vault

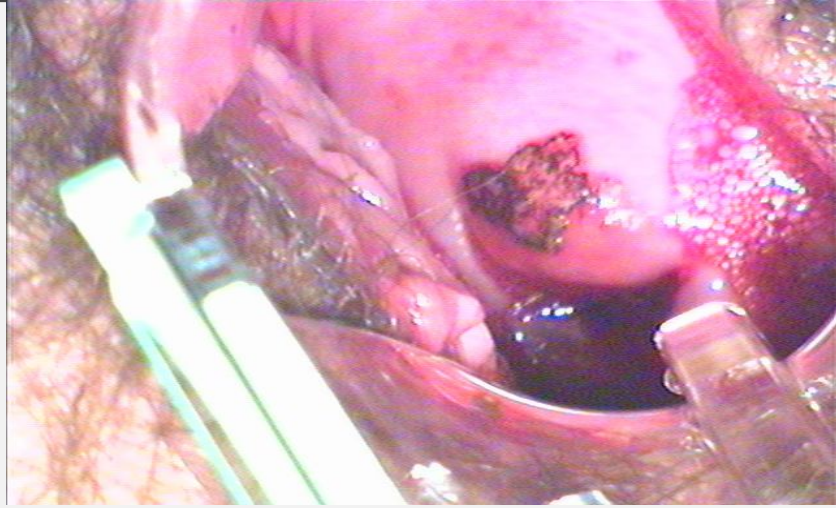


SPECULUM EXAM

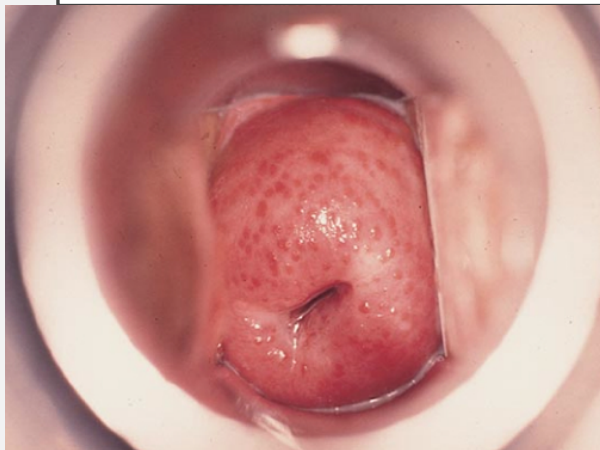Pay close attention  
To the borders of the  
Redness/erythema



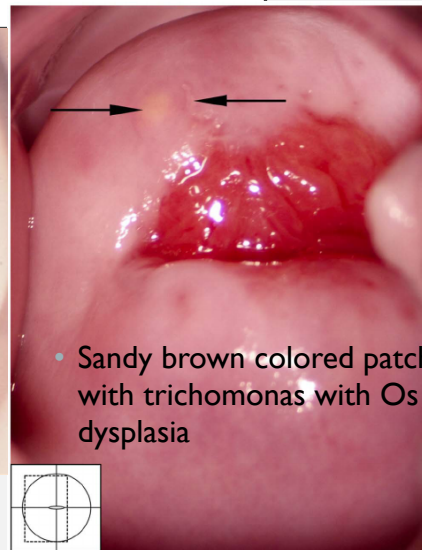
SPECULUM EXAM



SPECULUM EXAM



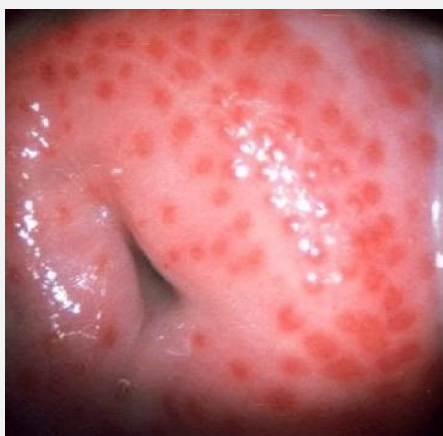- Strawberry cervix



- Sandy brown colored patches with trichomonas with Os dysplasia

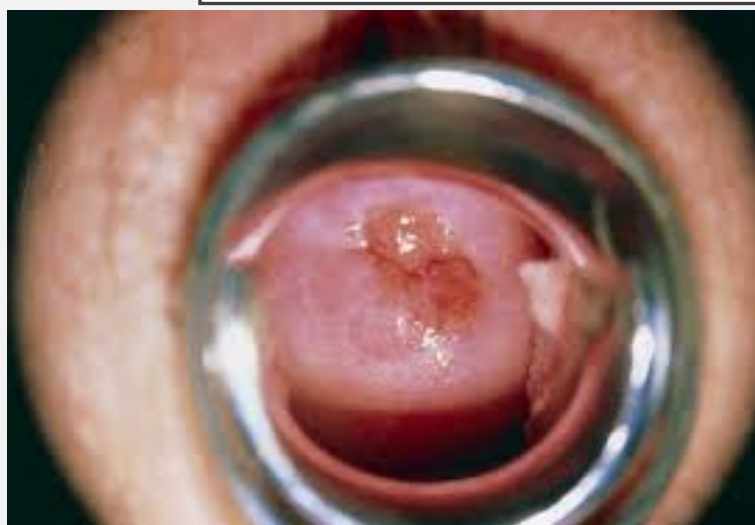

SPECULUM EXAM



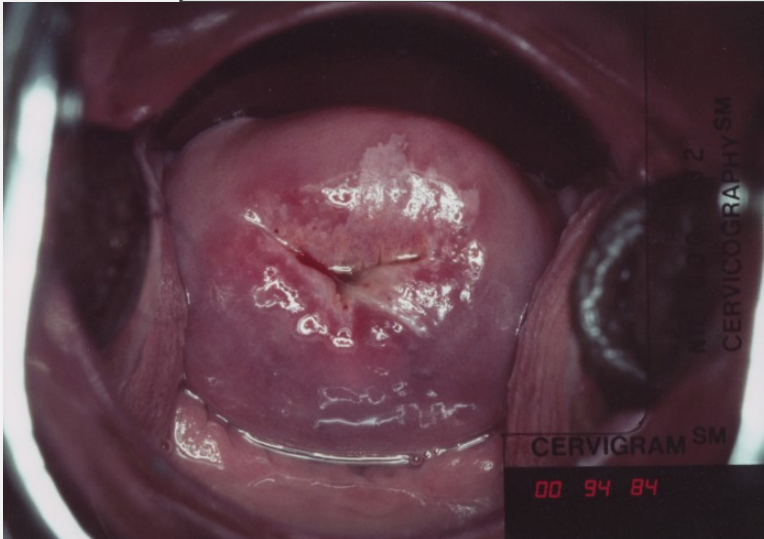
- Strawberry cervix

SPECULUM EXAM



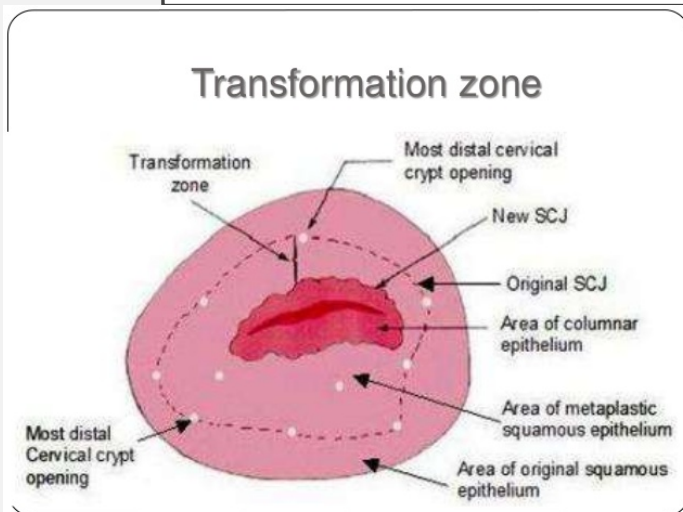
- Ectropion

### SPECULUM EXAM



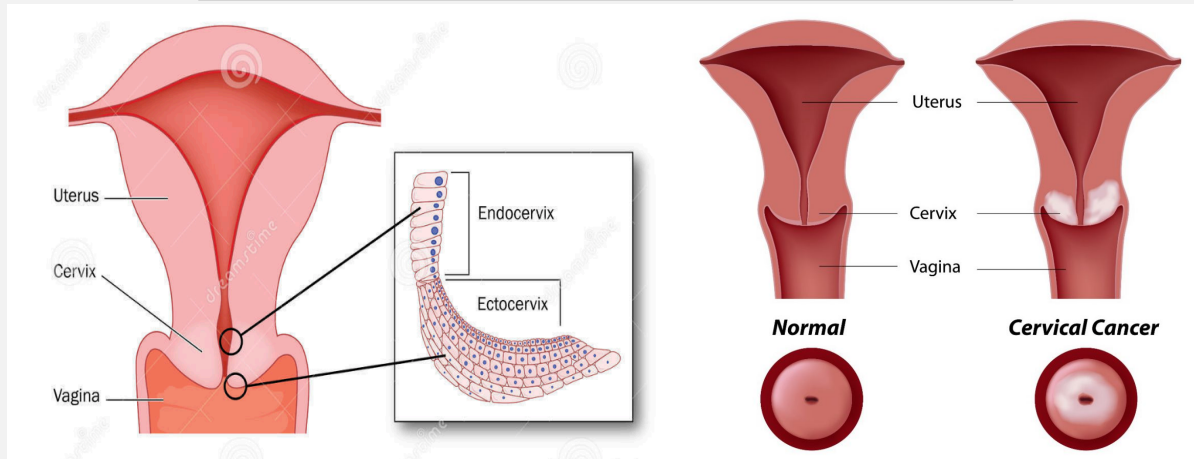
- Cervical Cancer around transformational zone

### SPECULUM EXAM



- Endocervix > ectocervix
- Columnar epithelium > into Squamous cells

## SPECULUM EXAM



## REMOVAL OF SPECULUM

- DO NOT allow speculum to snap shut – can cause injury/severe pain
- Unlock speculum + at the same time begin pulling speculum out (leave open slightly to avoid pinching vaginal walls) AND rotating speculum back to the sideways position to remove from vault
- Above should be done in one rapid step
- Discard speculum
- Promptly create microscope smear slides with the vaginal vault samples you collected
- Place swabs in a swab box and label accordingly (internal vaginal vault specimens)

### POINTS TO REMEMBER

- RNs cannot diagnose
- Review all findings with physician (+ photos)
- Immediate concerns, contact physician to enter room for assistance
- Patient can choose to decline speculum exam (will review more in depth)
- Photograph all findings or pertinent negatives
- Photograph findings PRIOR to removal
- Items removed from vaginal vault should be collected and placed in sterile towels, place INSIDE the kit to be processed at the crime lab for DNA

### POINTS TO REMEMBER

- Promptly create slide smear mounts for the crime lab, close them securely once finished
- Label the swab box internal specimens
- Use appropriate receptacle based on blood/type of fluid on speculum (regular trash or biohazard)

QUESTIONS?